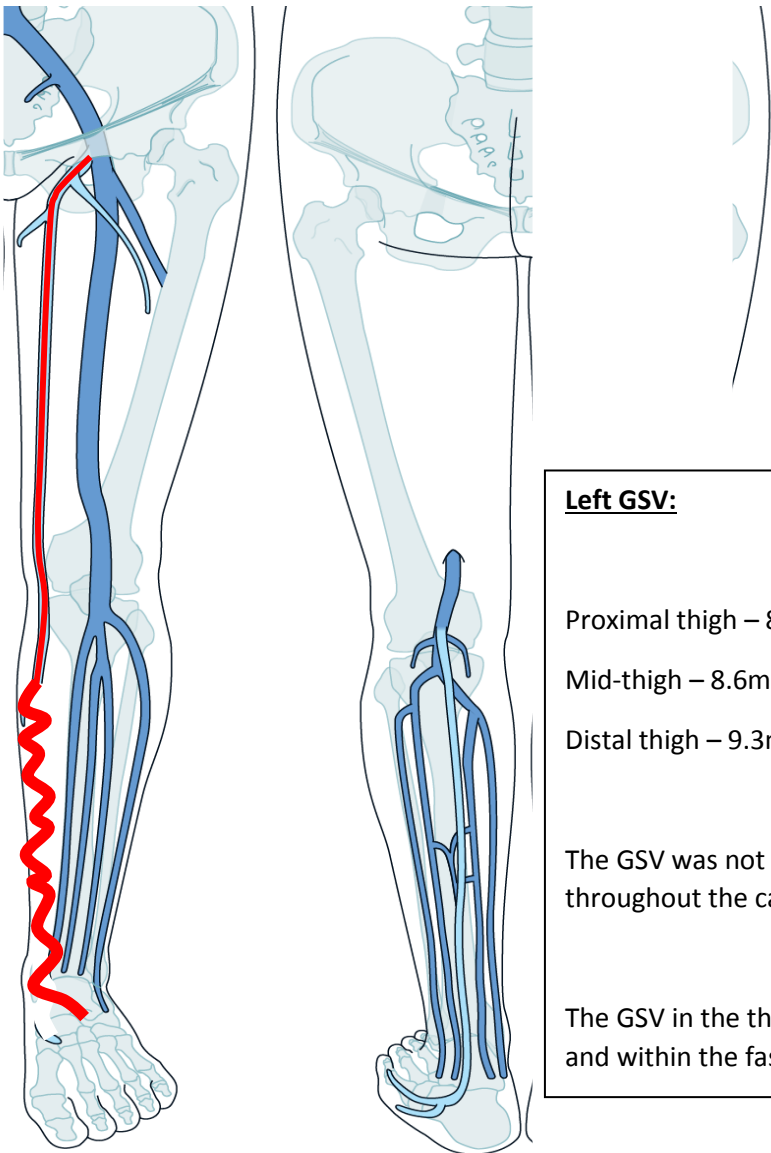


Vascular lab report

Assessed by: Suleman Choudhury

Anterior view

Posterior view



Left GSV:

Proximal thigh – 8.6mm
Mid-thigh – 8.6mm
Distal thigh – 9.3mm

The GSV was not visible throughout the calf.

The GSV in the thigh lies straight and within the fascia



red colour denotes reflux



Competent superficial vein



Competent deep vein



Deep vein scarring

US Doppler lower limb veins Lt:

The Sapheno-Femoral Junction (SFJ) and Greater Saphenous vein (GSV) are patent and incompetent. The GSV fills varices (9.1mm) in the proximal, medial aspect of the calf which courses to the foot. The GSV is not visible in the calf.

The Sapheno-Popliteal Junction (SPJ) and Short Saphenous vein (SSV) are patent and competent.

All deep veins are all patent and competent.

No incompetent perforators detected.
